

Insulation-Tipped Knife as an Endoscopic Treatment Method for Benign Anastomotic Stricture After Low Anterior Resection

Low Anterior Rezeksiyon Sonrası Gelişen Benign Anastomoz Darlığı için Endoskopik Tedavi Yöntemi Olarak Insulation-Tipped Knife

© Mehmet İbiş, © Mustafa Ergin

Gazi University Faculty of Medicine, Department of Gastroenterology, Ankara, Turkey

Abstract

Benign anastomotic strictures are one of the most common complications after low anterior resection. While endoscopic treatments such as balloon dilation can be applied to these strictures, some patients may require surgical treatment. We present a 65-year-old patient who developed benign anastomotic stenosis after low anterior resection, and the stenosis did not heal despite recurrent balloon dilatation, and we performed an incision with an Insulation-Tipped (IT) knife. After the incision with the IT knife, the patient is followed up asymptotically.

Key Words: Anastomotic Stenosis, Endoscopic Treatment, IT Knife Incision

Öz

Benign anastomoz darlıkları, low anterior rezeksiyon sonrası en sık görülen komplikasyonlardan biridir. Bu darlıklara balon dilatasyonu gibi endoskopik tedaviler uygulanabilirken bazı hastalarda cerrahi tedavi gerekebilir. Low anterior rezeksiyon sonrası semptomatik benign anastomoz darlığı gelişen ve tekrarlayan balon dilatasyonlarına rağmen darlığı iyileşmeyen, Insulation-Tipped (IT) knife ile insizyon yaptığımız 65 yaşında bir hastayı sunduk. IT knife ile yapılan tedavinin ardından hasta asemptomatik olarak takip edilmektedir.

Anahtar Kelimeler: Anastomoz Darlığı, Endoskopik Tedavi, IT Knife ile İnsizyon

Introduction

Benign stenosis is one of the common colorectal anastomosis complications after low anterior resection and occurs in approximately 5.8% to 20%. In most patients, anastomotic stenosis is a serious condition that may require repeated endoscopic treatment or surgery. We present a case in which we performed an Insulation-Tipped (IT) knife incision in a patient who developed symptomatic benign stenosis after low anterior resection and did not respond to recurrent endoscopic balloon dilatation treatment.

Case Presentation

Sixty-five year-old male patient. Low anterior resection operation was performed in 2014 due to rectosigmoid cancer. In the following years, anastomotic stenosis with an approximately 8 mm diameter lumen opening, which does not allow the passage of the standard colonoscope, was observed in the colonoscopic examination performed due to the complaints of thinning and swelling in the stool (Pictures 1, 2). There was no pathology in the biopsy samples taken from the stenosis anastomosis area. In imaging methods, the proximal part of the stenosis was normal, and the patient who was evaluated as a 4 mm long

Address for Correspondence/Yazışma Adresi: Mustafa Ergin

Gazi University Faculty of Medicine, Department of Gastroenterology, Ankara, Turkey

Phone: +90 505 325 83 68 E-mail: mstfergn@hotmail.com ORCID ID: orcid.org/0000-0002-9593-3705

Received/Geliş Tarihi: 13.05.2021 Accepted/Kabul Tarihi: 06.09.2022

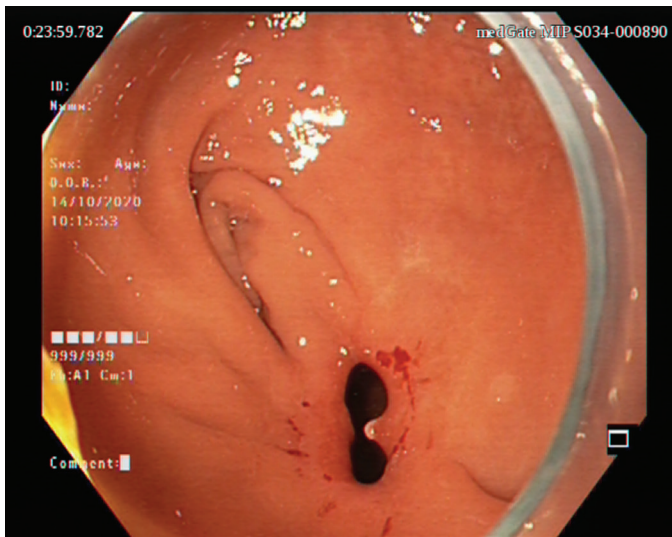
©Copyright 2022 Ankara University Faculty of Medicine

Journal of Ankara University Faculty of Medicine is published by Galenos Publishing House.

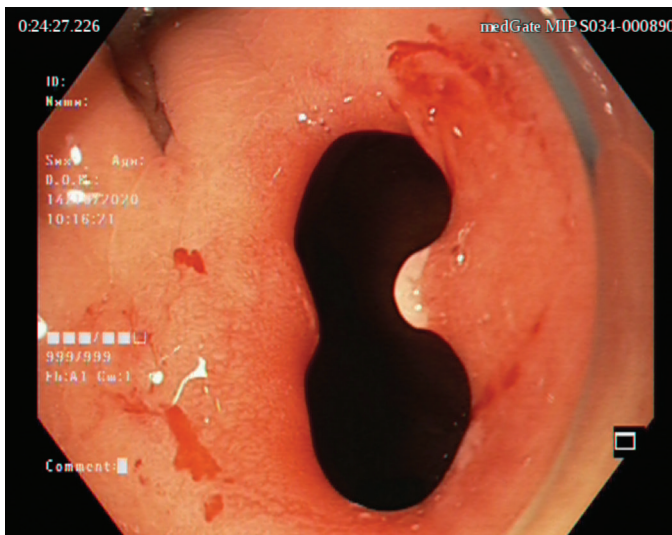
All content are under CC BY-NC-ND license.



short segment benign stenosis was applied repeated endoscopic balloon dilatation for five times. Balloon dilatation was applied effectively with 8-10, 10-12, 12-15 mm balloons, respectively, for every 2-3 weeks. It was seen that the stenosis reoccurred before each dilatation and did not allow the passage of the colonoscope. The patient's symptoms and the need for repeated dilatation continued. The anastomotic stenosis was then circumferentially incised with an IT knife from 6-7 locations, and an easy passage to the proximal part of the stenosis was achieved with the standard colonoscope (Pictures 3-5). During the follow-up, the patient had no symptoms and tolerated the procedure well (Picture 6). In the control colonoscopy after the treatment (2 weeks, 3 months and 1 year later), it was seen that the colonoscope passed easily through the anastomotic area.



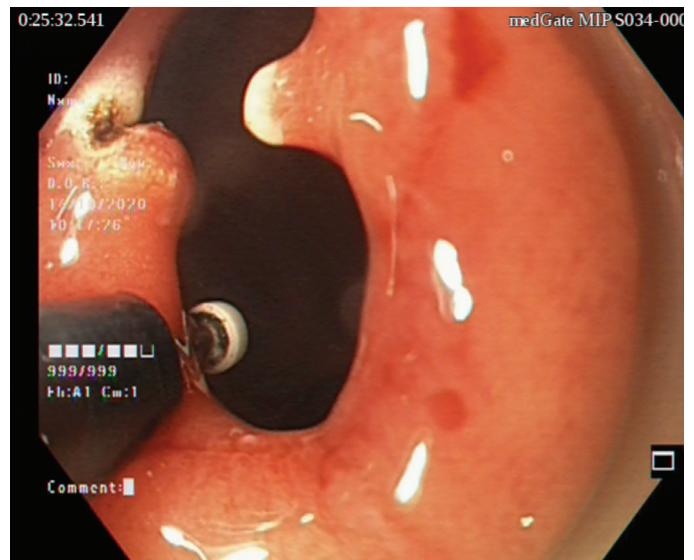
Picture 1: Appearance of anastomotic stenosis before IT knife treatment
IT: Insulation-Tipped



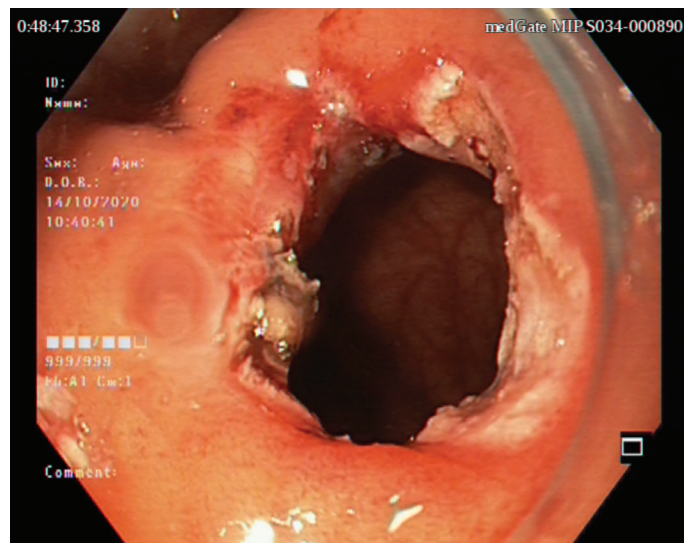
Picture 2: Close-up view of anastomotic stenosis before IT knife treatment
IT: Insulation-Tipped

Discussion

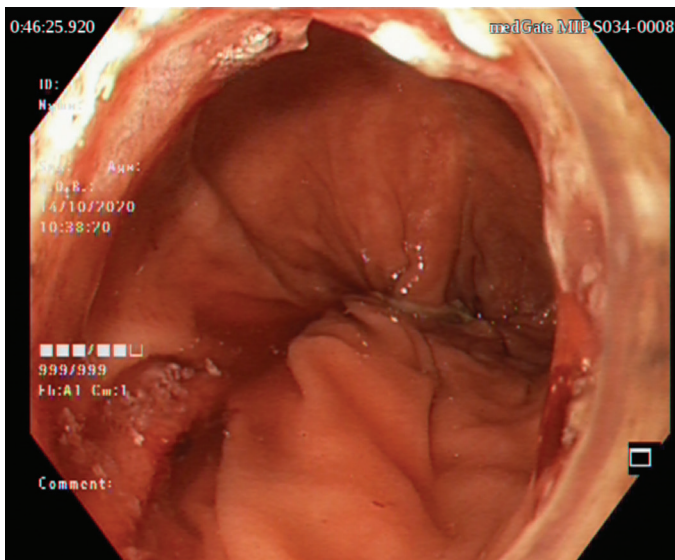
Benign anastomotic stenosis may develop in 5.8%-20% of colorectal anastomoses (1). This rate reaches 80% if colonoscopic examination is performed in the early postoperative period. Although the factors leading to the development of stenosis are not fully understood, conditions such as ischemia, leakage, and inflammation are blamed (2). There are conflicting publications regarding the relationship between anastomosis techniques and stenosis. Although some studies show that the risk of anastomosis increases with the use of staplers, there are also studies in the literature that express a contrary opinion (3,4). Our patient had an anastomosis with staplers and there was no postoperative fistula or leak. It is not necessary to intervene in



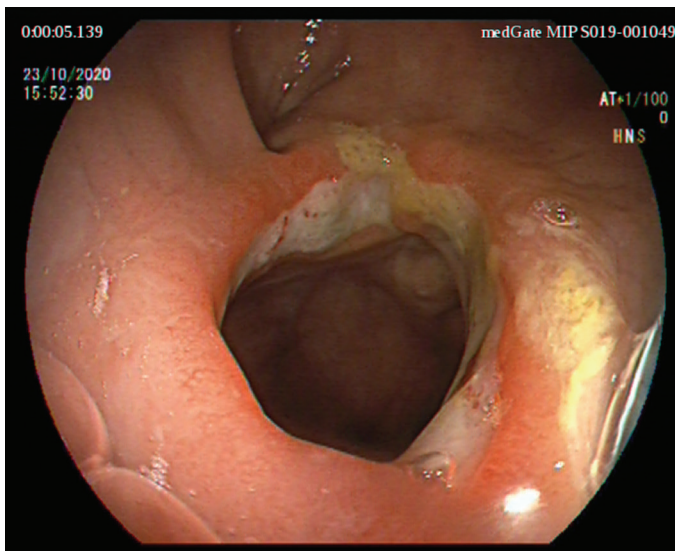
Picture 3: Image obtained during incision with IT knife
IT: Insulation-Tipped



Picture 4: View after completion of the incision



Picture 5: It is seen that the proximal stenosis can be passed easily with the colonoscope after the incision



Picture 6: Appearance two weeks after treatment

every anastomotic stricture. Treatment should be applied if the patient is symptomatic (2). In our patient, anastomotic stenosis did not allow the passage of the standard colonoscope and there were complaints such as bloating and thinning in stool calibration.

Treatment of biliary strictures developing after surgery varies from conservative methods to surgical treatment. The success of the treatment is the smooth passage of the standard colonoscope with a diameter of 13 mm and the regression of the symptoms (5).

The first treatment option should be endoscopic dilatation (bougie or balloon dilatation), except for strictures located low enough to be reached by rectal touch and can be dilated digitally

(1). If there is no response from this, dilatation or expandable metal stents can be used with endoscopic incision (6). Surgical treatment should be applied in cases where there is no response from endoscopic applications (2).

The IT knife is a knife with an insulator at its end, measuring 2.2 mm in diameter in order to avoid puncturing the tissue. It has been widely used for endoscopic submucosal dissection since its introduction by Mori et al. (7) in the late 1990s. Currently, a 4-mm long IT knife 2 is in use as an improvement over the original form, and other similar knives have been developed and are also in use. The IT knife can be used for pre-cutting around the lesion and for submucosal dissection. It can also be used to achieve hemostasis in cases where bleeding is not severe (8). It can also be used in the treatment of benign stenosis.

In our patient, repeated balloon dilatation was performed for the stenosis, but due to its failure, the patient was incised with an IT knife, considering the risk of morbidity and mortality caused by surgical treatment.

Ethics

Informed Consent: Informed consent was obtained from the patient.

Authorship Contributions

Surgical and Medical Practices: M.İ., M.E., Concept: M.E., Design: M.E., Data Collection or Processing: M.İ., M.E., Analysis or Interpretation: M.İ., M.E., Literature Search: M.İ., M.E., Writing: M.E.

Conflict of Interest: The authors declare that they have no conflict of interest.

Financial Disclosure: The authors declared that this study has received no financial support.

References

1. Curcio G, Spada M, di Francesco F, et al. "Completely obstructed colorectal anastomosis: a new non-electrosurgical endoscopic approach before balloon dilatation." *World J Gastroenterol.* 2010;16:4751-4754.
2. Yaman İ, Derici H. Endoscopic Dilatation of Benign Colonic Anastomotic Stricture. *Kolon Rektum Hast Derg.* 2010;20:134-138.
3. Pietropaolo, V. Masoni L, Ferrara M, Montori A. "Endoscopic dilation of colonic postoperative strictures." *Surgical Endoscopy.* 1990;4:26-30.
4. Delaunay-Tardy K, Barthélémy C, Dumas O, et al. "Endoscopic therapy of benign colonic post-operative strictures: report on 27 cases." *Gastroenterol Clin Biol.* 2003;27:610-613.
5. Di Giorgio P, De Luca L, Rivellini G, et al. "Endoscopic dilation of benign colorectal anastomotic stricture after low anterior resection: a prospective comparison study of two balloon types." *Gastrointest Endosc.* 2004;60:347-350.
6. Riditid W, Siripun A, Rerknimitr R. "Stricture at colorectal anastomosis: to dilate or to incise." *Endosc Int Open.* 2018;6:E340-E341.
7. Mori G, Nonaka S, Oda I, et al. "Novel strategy of endoscopic submucosal dissection using an insulation-tipped knife for early gastric cancer: near-side approach method." *Endosc Int Open.* 2015;3:E425-E431.
8. Choi HS, Chun HJ. "Accessory devices frequently used for endoscopic submucosal dissection." *Clin Endosc.* 2017;50:224.